



PATIENT

Elsa Leiken

SPECIES

Canine

BREED

Miniature Schnauzer

SEX

Female Spayed

AGE

11 years

WEIGHT

20lbs

INTERPRETED BY

Maggie Machen Lamy,
DVM, DACVIM
(Cardiology)

IMAGING PERFORMED BY

Julia Bakker, DVM

HOSPITAL NAME

Orange Blossom
Veterinary Imaging

REFERRING VET

Dr. Scibelli

INVOICE

46569

DATE

1/26/26

PRESENTING CLINICAL SIGNS

History: History of stage C mitral/tricuspid endocardiosis and generalized cardiomegaly. Over the past few weeks Elsa has had an increased frequency of coughing. CXR showed cardiomegaly. Bloodwork was submitted and increasing her furosemide to three times a day was recommended. However, yesterday PM O's note she seemed to have increased effort and was seeming worse than usual. O states that they woke up in the middle of the night to Elsa laterally. Had a syncopal episode February 2025.
-Current medications: Spironolactone 25mg SID, Vetmedin 2.5mg BID, Lasix 20mg 2-3x per day.

RADIOGRAPHIC FINDINGS *NOTE: Images submitted for supplemental cardiac information only.
Cardiomegaly with LA enlargement. No obvious evidence of CHF.

ECHOCARDIOGRAM FINDINGS

2D, m-mode, color flow and doppler imaging is available. The mitral valve is diffusely thickened with prolapse into the left atrial lumen. There is marked eccentric mitral regurgitation present. The MR velocity is normal. There is marked left atrial enlargement. There is mild left ventricular dilation. Left ventricular systolic function is hyperdynamic. Mild right atrial and ventricular dilation (subjective). Mild thickening of the tricuspid valve with moderate TR. Normal velocity. The aortic valve appears trileaflet with normal mobility. No significant AI. There is normal systolic flow velocity across the aortic valve. The main pulmonary artery is normal in diameter. The pulmonic valve is normal in appearance. Flow through the RVOT/PV is normal in velocity. Trace PI. No pericardial/pleural effusion or cardiac masses are seen.

CARDIAC CHART

CANINE CARDIAC PARAMETERS	MR VMAX (m/s)	TR VMAX (m/s)	LA/AO (Boon method)	LA/AO (Heart Base; Swe)	FS (%)	EF (%)	EPSS (cm)	
NORMAL PARAMETER	4.5-5.5	<2.7	1.3	<1.6	28-40	40-100	<0.6	
PATIENT	5.2	2.5	2.5	2.8	44	77	0.4	
CANINE CARDIAC PARAMETERS	HR (BPM)	AV VMAX (m/s)	PV MAX (m/s)	BODY WEIGHT (kg)	LA 2D short axis Base view (cm)	LVIDd Avg; 2D and m-mode short axis (cm)	LVIDs Avg; 2D and m-mode short axis (cm)	
NORMAL PARAMETER	50-100	0.7-1.7	0.7-1.6	BELOW	BELOW	BELOW	BELOW	
PATIENT	NM	1.8	0.8	9.1	3.7	4.3	2.4	
*Normal chamber parameters expressed as a mean value (SD)					3	1.27 (5.3)	2.46 (2.46)	1.36 (5.5)
BODY WEIGHT DEPENDENT PARAMETERS					5	1.40 (4.5)	2.74 (5.2)	1.60 (4.7)
*Note: All measurements based upon multi-modal images and methods. An average value is reported.					10	1.50 (3.8)	3.27 (3.5)	2.06 (3.1)
					15	1.83 (2.0)	3.71 (2.4)	2.43 (2.1)
					20	2.02 (1.9)	4.14 (2.2)	2.80 (2.0)
					25	2.18 (2.4)	4.48 (2.9)	3.10 (2.5)
					30	2.33 (3.3)	4.83 (3.9)	3.39 (3.4)
					35	2.48 (4.3)	5.17 (5.0)	3.69 (4.5)
					40	2.62 (5.2)	5.48 (6.1)	3.96 (5.4)
					50	2.88 (7.1)	6.07 (8.3)	4.46 (7.4)

Adapted from June Boon, Veterinary Echocardiography, 1998
Rishniw M and Hollis NE, J Vet Intern Med 2000; 14:429-435
Hansson et al, Vet Rad and Ultrasound 2002
Bonagura et al. Echocardiography: principles of interpretation, Vet Clin North Am 15:1177, 1995



PATIENT

Elsa Leiken

SPECIES

Canine

BREED

Miniature Schnauzer

SEX

Female Spayed

AGE

11 years

WEIGHT

20lbs

INTERPRETED BY

Maggie Machen Lamy,
DVM, DACVIM
(Cardiology)

IMAGING PERFORMED BY

Julia Bakker, DVM

HOSPITAL NAME

Orange Blossom
Veterinary Imaging

REFERRING VET

Dr. Scibelli

INVOICE

46569

DATE

1/26/26

INTERPRETATION OF THE FINDINGS & FURTHER RECOMMENDATIONS

The cause of the murmur is chronic degenerative valve disease causing marked mitral and moderate tricuspid regurgitation. Marked left atrial enlargement indicates the risk for spontaneous congestive heart failure is elevated. No additional issues are identified.

Given these findings, a prior diagnosis of congestive heart failure (stage C) is certainly supported in this case. The cause of the current cough is elusive as active congestion is not apparent on CXR; however, an increase in Lasix is recommended. Monitoring of sleeping respiratory rates will be paramount to screen for congestive heart failure at home. Cough suppression to improve QOL can also be considered (hydrocodone, 0.2-0.4mg/kg up to q4-6h PRN) for any residual mechanical cough in the face of normal sleeping respiratory rates. If able to be stabilized, the average survival time of canine patients with active pulmonary edema is 8-9 months on medications; however, most are able to maintain a good quality of life for that period on medications. Patient will always be at risk for recurrent CHF, development of arrhythmias/LA tear, syncope and/or sudden death in the future.

Omega fatty acid supplementation and mild salt restriction may also be of some long-term benefit. Monitor for acute progression of the cough, labored breathing, exercise intolerance or collapse episodes in the future.

Elective anesthesia is not advised, as there is high risk for complication.

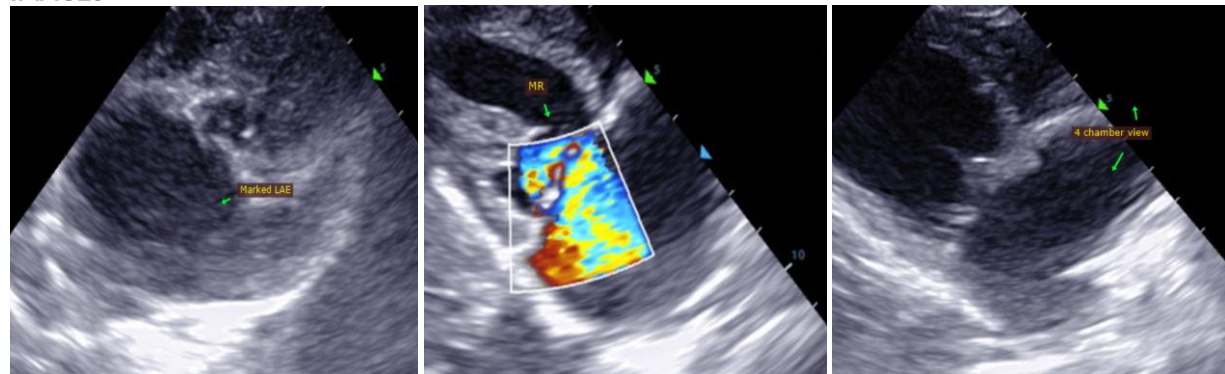
PLAN

Increase Pimobendan to 0.3mg/kg PO q8h. Continue Lasix 20mg PO q8h. Increase Spironolactone to 25mg PO q12h.

Monitor renal values and BP in 10-14 days, then every 3-4 months while on diuretics to ensure tolerance of medications. If doing well at home, renal values are reasonable and BP >130mmHg, administer ACEI 0.5mg/kg PO q12h. Consider hydrocodone if needed for QOL.

Recommend conservative monitoring with a recheck echocardiogram in 6 months, sooner if any development of associated clinical signs occurs in the interim.

IMAGES



The information and recommendations provided are based on the images presented by the referring veterinarian. No evaluation can be communicated regarding pathology that was not visible in the image/video clips provided.



PATIENT

Elsa Leiken

SPECIES

Canine

BREED

Miniature Schnazuer

SEX

Female Spayed

AGE

11 years

WEIGHT

20lbs

INTERPRETED BY

Maggie Machen Lamy,
DVM, DACVIM
(Cardiology)

IMAGING PERFORMED BY

Julia Bakker, DVM

HOSPITAL NAME

Orange Blossom
Veterinary Imaging

REFERRING VET

Dr. Scibelli

INVOICE

46569

DATE

1/26/26

Thank you for this referral. This report was generated using transcription software, and minor dictation errors may be present. If the clinical or image interpretation does not parallel your findings or if I can be of any further assistance, please contact me.

Maggie Machen Lamy, DVM
Diplomate of the American College of Veterinary Internal Medicine (Cardiology)
info@sonopath.com